

## The Evolution of the Hughes Tarsconjunctival Flap for Lower Eyelid Reconstruction

Rod J. Rohrich, M.D., and Ross I. S. Zbar, M.D.

Dallas, Texas

**Learning Objectives:** After studying this article, the participant should be able to: 1. Compare and contrast the original Hughes flap to its subsequent modifications. 2. Understand the importance of preserving the inferior portion of the upper eyelid tarsal plate at the donor site. 3. Discuss the advantages and disadvantages of buttonholing the pedicled tarsconjunctival flap. 4. Summarize the various methods of dividing the pedicled tarsconjunctival flap. 5. State the indications for a free tarsconjunctival graft. 6. Review the technique required to perform a free tarsconjunctival graft for lower eyelid full-thickness defect reconstruction.

The Hughes tarsconjunctival flap was initially described in 1937. This flap is best used for reconstructing full-thickness defects involving the central portion of the lower eyelid. The evolution of this flap over the last 60 years is outlined. Several important modifications are presented; these modifications lead to decreased donor-site morbidity and improved recipient site outcome. (*Plast. Reconstr. Surg.* 104: 518, 1999.)

Lower-eyelid reconstruction after cancer excision or trauma is a challenging undertaking. To achieve both excellent functional and aesthetic results, the layers of the lower eyelid must be successfully reconstructed. These layers include the posterior lamella, consisting of the conjunctiva and the tarsal plate, and the anterior lamella, consisting of the pretarsal orbicularis oculi muscle and the lower eyelid skin. We describe the evolution of the Hughes flap for lower eyelid reconstruction.

### THE ORIGINAL HUGHES FLAP

In 1937, Hughes<sup>1</sup> described a method for lower lid reconstruction that used the upper lid as the donor site. A tarsconjunctival flap fashioned from the ipsilateral upper eyelid was designed based on the superior conjunctiva, and it was advanced inferiorly into the lower eyelid to replace the absent posterior lamella. Hughes split the upper lid at the mucocutane-

ous junction and created two flaps. The inner flap consisted of conjunctiva and tarsus, whereas the outer flap consisted of subcutaneous tissue and skin with the lashes attached. This dissection was carried upward 3 mm beyond the tarsus, between the levator/Mueller's muscle complex and the subcutaneous tissue (Fig. 1). The inner flap was brought downward and attached to the lower lid conjunctiva at the point of surgical resection to rebuild the posterior lamella. Mueller's muscle and the levator aponeurosis remained attached to the tarsal plate. Hughes undermined cheek skin until it could be elevated to replace absent lower lid skin without tension. This undermined cheek skin was then brought upward and sewn onto the anterior portion of the lower half of the upper lid tarsal plate to rebuild the anterior lamella. A second stage at 4 weeks was required for free transplantation of the upper lid eyelashes, and a third stage (after an additional 12 weeks) was required for division and inset of the flap. Hughes also described a reversed Hughes flap for the repair of the upper lid, with the lower lid as the donor.

In 1945, Hughes again published a detailed account of his flap for lower-lid reconstruction.<sup>2</sup> There were essentially no modifications from his original method.



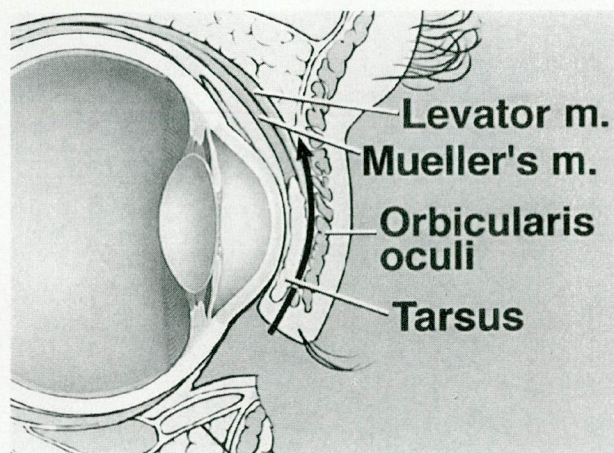


FIG. 1. Schematic diagram of the Hughes flap as originally described in 1937. Note that the plane of dissection is superficial to the levator complex.

The main problem with his original technique was postoperative donor-site morbidity. The upper lid frequently underwent retraction and entropion after dividing the pedicle.

#### FULL-THICKNESS SKIN GRAFTING OF THE HUGHES FLAP

In 1954, Macomber et al.<sup>3</sup> recognized some of the shortcomings of the Hughes flap and attempted to rectify them. Rather than advance the cheek skin upward and risk future ectropion of the lower eyelid caused by gravitation pull, Macomber et al. used a full-thickness skin graft harvested from either the postauricular, supraclavicular, or contralateral upper lid skin. This graft was sewn onto the advanced tarsal plate. The blood supply for the graft came from the tarsoconjunctival flap. Macomber et al. also recognized that the eyelashes were more anatomically functional on the upper lid for blink reflex and less important on the lower lid. Accordingly, they recommended eyelash transplantation only in the young or aesthetically minded patient after several weeks. They used a single row of hair follicles from the eyebrow for this purpose. After 6 weeks, they divided the lid.

This was a significant improvement in the design of the Hughes flap. By eliminating the elevation and advancement of cheek skin, there was less downward pull on the reconstructed lower lid, which was the main cause of postoperative lower lid ectropion.

#### MODIFIED HUGHES FLAP

Hughes published further technical details and revisions, which he had subsequently de-

veloped for lower lid reconstruction, 40 years after his first article.<sup>4</sup> His modifications were in response to criticisms about postoperative outcome. Most significantly, Hughes changed the location of his lid-splitting incision and the plane of dissection (Fig. 2). Rather than starting the transverse incision at the mucocutaneous junction of the upper eyelid, Hughes made an oblique cut through the tarsus at the margin of the lid. This resulted in two improvements: (1) it better preserved the eyelash root bulbs, thereby decreasing potential hair loss; and (2) it created a thinner flap to be united with the lower lid conjunctiva. Hughes stressed that the oblique cut into the tarsus must begin at the conjunctival margin, not higher. He argued that those authors who placed the incision above the lid margin lessened the amount of tarsus available and put too much stretch on the upper lid. However, it was an attempt to decrease donor-site morbidity that led Cies and Bartlett<sup>5</sup> and Pollock et al.<sup>6</sup> to leave the inferior portion of the upper eyelid tarsal plate in situ by placing the incision above the lid margin. These authors argued that this maneuver preserved upper eyelid support and decreased postoperative upper eyelid retraction, entropion, and trichiasis.

Hughes also revised his plane of dissection, creating a true tarsoconjunctival flap. His revision described severing the levator and Mueller's muscle attachments to the tarsus and hugging the conjunctiva. Dissection, therefore, proceeded along the tarsal plate to the upper border of the tarsus. The plane of dissection was then brought adjacent to the conjunctiva

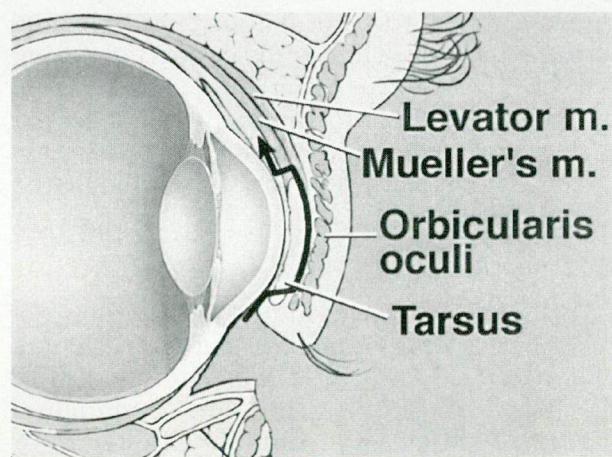


FIG. 2. Schematic diagram of the Hughes flap as subsequently modified by Hughes in 1976. Note the new plane of dissection, which creates a true tarsoconjunctival flap, and the oblique cut through the tarsal plate.



by cutting through the attachments of the levator aponeurosis and Mueller's muscle. Vertical incisions were placed laterally and medially in the tarsoconjunctival flap to allow downward pull of the flap. Superior dissection was generous enough to allow easy downward movement of the tarsoconjunctival flap. These changes were instituted to decrease donor-site complications. Hughes stated that if the dissection was not carried high enough or the levator and Mueller's muscle attachments were not severed from the tarsal plate, entropion and retraction of the upper eyelid were very likely to occur. This modification was similar to that described previously by Cies and Bartlett.<sup>5</sup>

In the article published in 1976 by Hughes,<sup>4</sup> Beard commented on the Hughes flap. Beard reiterated the need to bring down conjunctiva, which is abundant, and not the levator or Mueller's muscle to prevent upper lid retraction. He also suggested making a peephole in the flap to inspect the eye postoperatively.

In 1981, McCord and Nunery<sup>7</sup> described their method of harvesting the modified Hughes flap in detail. In contrast to Hughes<sup>4</sup> and in support of others,<sup>5,6</sup> McCord and Nunery<sup>7</sup> stated that the horizontal inferior edge of the Hughes flap must be at least 4 mm away from the lid margin for sufficient tarsal plate to remain in the upper eyelid donor site, thereby preventing postoperative deformity. This opinion was subsequently supported by the anatomical studies of Zide and Jelks,<sup>8</sup> who found the vertical height of the upper eyelid tarsal plate varied between 9 and 11 mm, whereas the vertical height of the lower eyelid tarsal plate was between 3.8 and 4.5 mm. Of interest, McCord and Nunery<sup>7</sup> initially described the best plane of dissection for raising the Hughes flap as being between Mueller's muscle and the levator aponeurosis; however, they acknowledged that some surgeons preferred to exclude Mueller's muscle from the flap altogether (Fig. 3).

#### *Continued Evolution*

In 1986, Doxanas<sup>9</sup> modified the Hughes procedure by adding orbicularis oculi muscle mobilization. He noted that placing a full-thickness skin graft over the tarsoconjunctival flap on the lower lid forced blood destined for the graft to diffuse from the conjunctiva through the essentially avascular tarsal plate to reach the graft. Doxanas believed this contributed to a rigid reconstruction. To avoid this, he

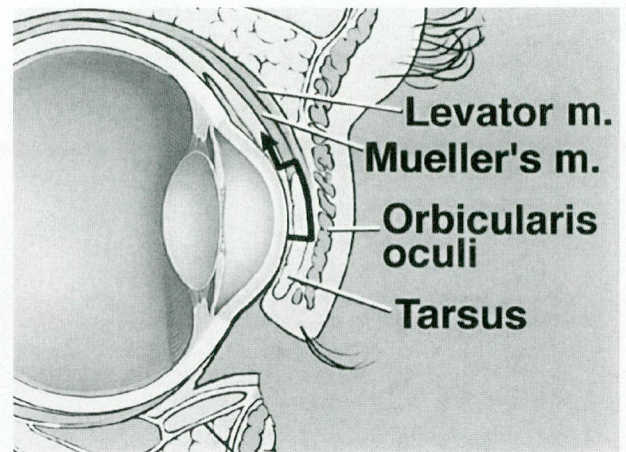


FIG. 3. Schematic diagram of the modified Hughes flap (after Cies and Bartlett<sup>5</sup> and McCord and Nunery<sup>7</sup>). Note how a portion of the tarsal plate is left in the donor site, thereby reducing postoperative donor-site complications. A true tarsoconjunctival flap is elevated.

mobilized the remaining lower lid preseptal orbicularis oculi muscle over the tarsoconjunctival flap by leaving it bipediced at the medial and lateral canthi to provide a vascular bed for the full-thickness skin graft. With this additional vascularity, all of his grafts were softer and more mobile. Lowry et al.<sup>10</sup> demonstrated that this modification yielded electromyographic activity during voluntary orbicularis contraction postoperatively in the lower lid, thereby potentially enhancing the functional results of the reconstruction.

#### *Buttonholing the Hughes Flap*

It was not until 1993 that Leibsohn et al.<sup>11</sup> studied the effect of intentionally buttonholing the Hughes flap, as initially suggested by Beard.<sup>4</sup> They believed that this procedure would allow for possible use of the eye and permit inspection of underlying ocular problems. They placed the buttonhole by making a vertical incision 15 mm in length in the central portion of the flap. No flaps were vascularly compromised. Unfortunately, few patients could actually take advantage of the buttonhole for useful vision because tightness of the flap resulted in closed eyelids. Furthermore, several patients experienced contraction of the hole. However, by manually opening the eyelids, the underlying ocular structures could be inspected through the buttonhole. Overall, the authors believed that this maneuver did not jeopardize flap viability, and it permitted postoperative inspection of the eye. Simply making a notch in the medial or lateral edge of the flap



to permit vision in certain fields of gaze without compromising flap blood supply might be of greater benefit.

#### *Modifications of the Division and Inset of the Hughes Flap*

Hughes initially left his flap pedicled for 3 months.<sup>1,2</sup> Cies and Bartlett<sup>5</sup> reported dividing the flap between 3 and 4 weeks without complications, and McCord and Nunery<sup>7</sup> waited 6 to 8 weeks before division.

Bartley and Putterman,<sup>12</sup> in 1995, described a method to reduce postoperative chronic hyperemia of the lower lid after transection of the pedicled Hughes flap. Rather than transecting the pedicle of the Hughes flap slightly superiorly to the new lower eyelid margin and suturing this to the lower eyelid skin,<sup>4,7</sup> they divided the tarsoconjunctival pedicle flush with the lower lid and allowed spontaneous granulation. This permitted the mucocutaneous junction to form through secondary intention and alleviated postoperative hyperemia.

#### *One-Stage Hughes Flap*

Interest in a one-stage lower eyelid reconstruction for the infirm or monocular patient led to the development of the free tarsoconjunctival graft. The tarsoconjunctival graft from the upper eyelid is harvested in an identical fashion to its pedicled counterpart, leaving 3 to 4 mm of the inferior tarsal plate in the donor site.<sup>13,14</sup> The donor site is allowed to heal by secondary intention. The graft is then used to reconstruct the posterior lamella of the lower eyelid defect. However, it is the anterior lamella that provides the vascular support for the free tarsoconjunctival graft. The best method for supporting this graft is a bipedicled advancement or rotation flap of the skin-muscle complex from the surrounding lower eyelid, cheek, or temporal tissue.<sup>9,13-19</sup>

#### CONCLUSIONS

The evolution of the Hughes flap for full-thickness lower eyelid reconstruction is described. By using this flap for central lesions of the lower eyelid that measure 60 to 80 percent of the total length of the lower eyelid, successful reconstructions can be obtained.

Several key points, however, must be stressed to achieve positive outcomes. (1) The tarsoconjunctival flap is raised beginning at least 3 to 4 mm above the lid margin, thus ensuring that adequate support remains in the donor site

and travels to the recipient site. (2) The best plane of dissection for the modified Hughes flap requires transection of both Mueller's muscle and the levator aponeurosis at the superior edge of the tarsal plate. Dissection proceeds subadjacent to the conjunctiva, creating a true tarsoconjunctival flap. (3) When using a pedicled Hughes flap, an adequately thinned full-thickness skin graft is used to cover the anterior surface of the tarsoconjunctival flap. This donor site may be the contralateral upper eyelid, the postauricular skin, or the supraclavicular skin. (4) After dividing the flap after 3 to 6 weeks, the mucocutaneous line is allowed to heal by secondary intention, thereby further decreasing postoperative edema. (5) When using a free tarsoconjunctival graft, the anterior lamella must provide adequate vascularity for support.

Using these principles will yield successful lower eyelid reconstructions with the Hughes flap technique. Common complications, such as an uneven lower eyelid, bulky reconstruction, entropion, ectropion, or trichiasis will be minimized.

Rod J. Rohrich, M.D.

Department of Plastic and Reconstructive Surgery  
University of Texas Southwestern Medical Center  
at Dallas

5323 Harry Hines Blvd

Dallas, Texas 75235

rrohric@mednet.swmed.edu

#### REFERENCES

1. Hughes, W. L. A new method for rebuilding a lower lid: Report of a case. *Arch. Ophthalmol.* 17: 1008, 1937.
2. Hughes, W. L. Reconstruction of the lids. *Am. J. Ophthalmol.* 28: 1203, 1945.
3. Macomber, W. B., Wang, M. K., and Gottlieb, E. Epithelial tumors of the eyelids. *Surg. Gynecol. Obstet.* 98: 331, 1954.
4. Hughes, W. L. Total lower lid reconstruction: Technical details. *Trans. Am. Ophthalmol. Soc.* 74: 321, 1976.
5. Cies, W. A., and Bartlett, R. E. Modification of the Mustardé and Hughes methods of reconstructing the lower lid. *Ann. Ophthalmol.* 7: 1497, 1967.
6. Pollock, W. J., Colon, G. A., and Ryan, R. F. Reconstruction of the lower eyelid by a different lid-splitting operation. *Plast. Reconstr. Surg.* 50: 184, 1972.
7. McCord, C. D., Jr., and Nunery, W. R. Reconstructive Procedures of the Lower Eyelid and Outer Canthus. In C. D. McCord, Jr. (Ed.), *Oculoplastic Surgery*. New York: Raven Press, 1981. Pp. 194-198.
8. Zide, B. M., and Jelks, G. W. *Surgical Anatomy of the Orbit*. New York: Raven Press, 1985. P. 32.
9. Doxanas, M. T. Orbicularis muscle mobilization in eyelid reconstruction. *Arch. Ophthalmol.* 104: 910, 1986.
10. Lowry, J. C., Bartley, G. B., and Litchy, W. J. Electro-



- myographic studies of the reconstructed lower eyelid after a modified Hughes procedure. *Am. J. Ophthalmol.* 119: 225, 1995.
11. Leibsohn, J. M., Dryden, R., and Ross, J. Intentional buttonholing of the Hughes flap. *Ophthalmic Plast. Reconstr. Surg.* 9: 135, 1993.
  12. Bartley, G. B., and Putterman, A. M. A minor modification of the Hughes operation for lower eyelid reconstruction. *Am. J. Ophthalmol.* 119: 96, 1995.
  13. Leone, C. R., Jr., and Hand, S. I., Jr. Reconstruction of the medial eyelid. *Am. J. Ophthalmol.* 87: 797, 1979.
  14. Beyer, C. K., and Bathrick, M. E. One stage lower eyelid reconstruction. *Ophthalmic Surg.* 13: 551, 1982.
  15. Stephenson, C. M. Reconstruction of the eyelid using a myocutaneous island flap. *Ophthalmology* 90: 1060, 1983.
  16. Putterman, A. M. Combined viable composite graft and temporal semicircular skin flap procedure. *Am. J. Ophthalmol.* 98: 349, 1984.
  17. Stephenson, C. M., and Brown, B. Z. The use of tarsus as a free autogenous graft in eyelid surgery. *Ophthalmic Plast. Reconstr. Surg.* 1: 43, 1985.
  18. Hawes, M. J. Free autogenous grafts in eyelid tarsoconjunctival reconstruction. *Ophthalmic Surg.* 18: 37, 1987.
  19. Leone, C. R., Jr., and VanGemart, J. V. Lower lid reconstruction using tarsoconjunctival grafts and bipediced skin-muscle flap. *Arch. Ophthalmol.* 107: 758, 1989.

**Self-Assessment Examination follows on  
the next page.**